
Patient:	Srajan Garg	Procedure:	Upper GI endoscopy
MRN:	165152	Date:	04/07/2025
DOB:	10/1/1996	Attending Physician:	Divya Mallam
Sex at Birth:	Male		
Age:	28 year(s)		

Additional Staff:

- Chabeli Castillo; Gem Manalo, MD

Indications:

- Exclusion of eosinophilic esophagitis
 - Heartburn
-

Medications:

- Propofol IV (White Bottle - NDC - 00409-6010-02) 350 mg
- Monitored Anesthesia Care

Complications:

- No immediate complications.

Estimated Blood Loss:

- Estimated blood loss: None.
-

Procedure:

- The 552 was introduced through the mouth and advanced to the second part of the duodenum.
- The upper GI endoscopy was accomplished without difficulty.
- The patient tolerated the procedure well.

Findings:

- The Z-line was regular and was found 41 cm from the incisors.
- Mucosal changes including ringed esophagus, longitudinal furrows, white plaques and congestion (edema) were found in the lower third of the esophagus and in the mid esophagus. Esophageal findings were graded using the Eosinophilic Esophagitis Endoscopic Reference Score (EoE-EREFS) as: Edema Grade 1 Present (decreased clarity or absence of vascular markings), Rings Grade 1 Mild (subtle circumferential ridges seen on esophageal distension), Exudates Grade 1 Mild (scattered white lesions involving less than 10 percent of the esophageal surface area), Furrows Grade 1 Mild (vertical lines without visible depth) and Stricture none (no stricture found). Biopsies were taken with a cold forceps for histology. Biopsies were obtained in the lower third of the esophagus and in the middle third of the esophagus with cold forceps for histology.
- The gastroesophageal flap valve was visualized endoscopically and classified as Hill Grade III (minimal fold, loose to endoscope, hiatal hernia likely).
- Patchy moderately erythematous mucosa was found in the gastric antrum, in the gastric body and in the gastric fundus. Biopsies were taken with a cold forceps for Helicobacter pylori testing.
- The examined duodenum was normal.

Impression:

- Z-line regular, 41 cm from the incisors.
- Esophageal mucosal changes suggestive of eosinophilic esophagitis. Biopsied.
- Biopsies were obtained in the lower third of the esophagus and in the middle third of the esophagus.
- Gastroesophageal flap valve classified as Hill Grade III (minimal fold, loose to endoscope, hiatal hernia likely).
- Erythematous mucosa in the antrum, gastric body and gastric fundus. Biopsied.
- Normal examined duodenum.

Recommendation:

- Discharge patient to home (with escort).
- Patient has a contact number available for emergencies. The signs and symptoms of potential delayed complications were discussed with the patient. Return to normal activities tomorrow. Written discharge instructions were provided to the patient.
- Resume previous diet.
- Await pathology results.
- Continue present medications.
- Return to GI clinic in 2 weeks.

Procedure Code(s):

- 43239, Esophagogastroduodenoscopy, flexible, transoral; with biopsy, single or multiple

Diagnosis Code(s):

- R12, Heartburn
- K22.89, Other specified disease of esophagus

Patient: Srajan Garg
MRN: 165152
DOB: 10/1/1996
Sex at Birth: Male
Age: 28 year(s)

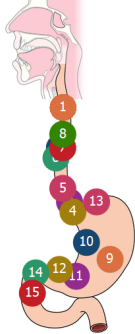
Procedure: Upper GI endoscopy
Date: 04/07/2025
Attending Physician: Divya Mallam

- K31.89, Other diseases of stomach and duodenum

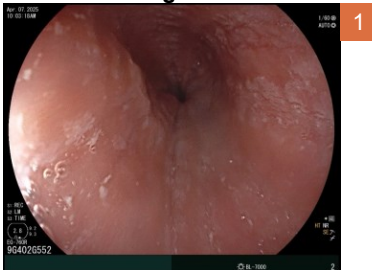CPT® - 2023© American Medical Association. All Rights Reserved.

The CPT codes, CCI edits and ICD codes generated are intended as suggestions and were generated based on input data. These codes are preliminary and upon coder review may be revised to meet current compliance and payer requirements. The provider is responsible for the final determination of appropriate codes, and modifiers.

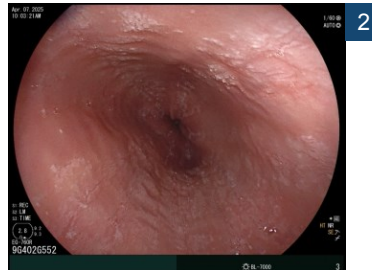Diagram(s):



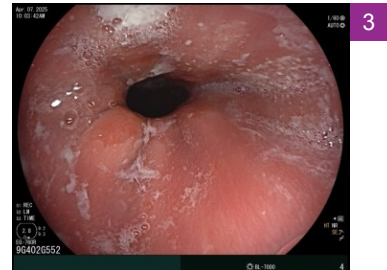
Procedure Images:



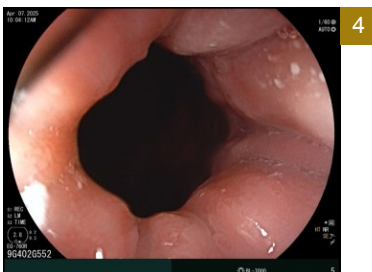
Normal, Upper Third Of The Esophagus



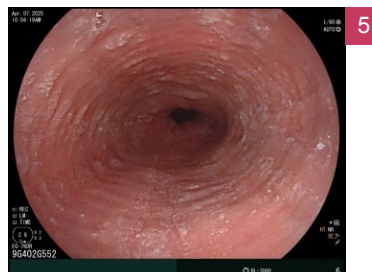Middle Third Of The Esophagus



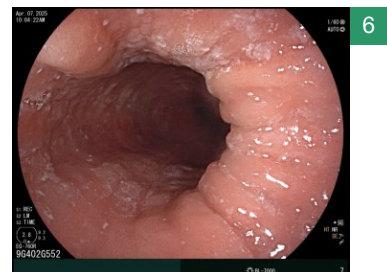
Lower Third Of The Esophagus



Gastroesophageal Junction



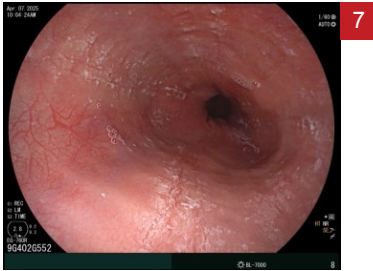
Lower Third Of The Esophagus



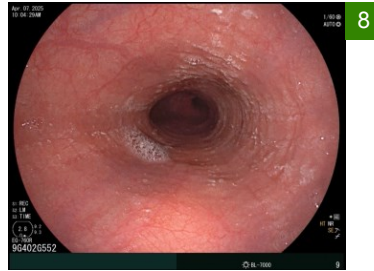Middle Third Of The Esophagus

Patient: Srajan Garg
MRN: 165152
DOB: 10/1/1996
Sex at Birth: Male
Age: 28 year(s)

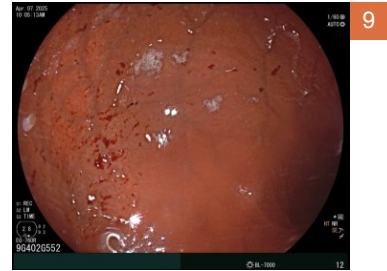
Procedure: Upper GI endoscopy
Date: 04/07/2025
Attending Physician: Divya Mallam



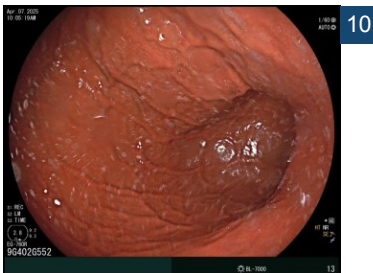Middle Third Of The Esophagus



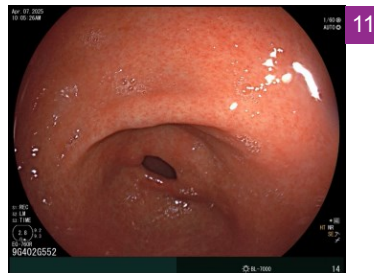Middle Third Of The Esophagus



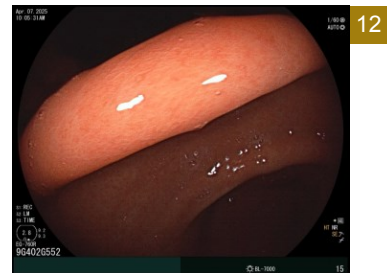
Gastric Body



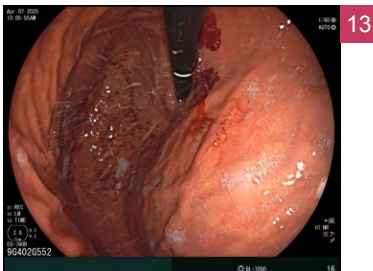
Gastric Body



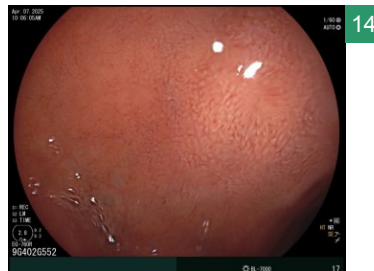Gastric Antrum



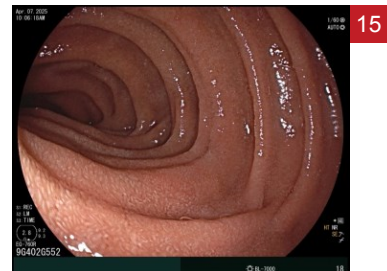Normal, Incisura Of The Stomach



Gastric Fundus



Normal, Duodenal Bulb



Normal, 2nd Portion Of The Duodenum

Divya Mallam

Divya Mallam

This document has been electronically signed.

Note Initiated: 04/07/2025

Note Completed: 04/07/2025 10:22 AM